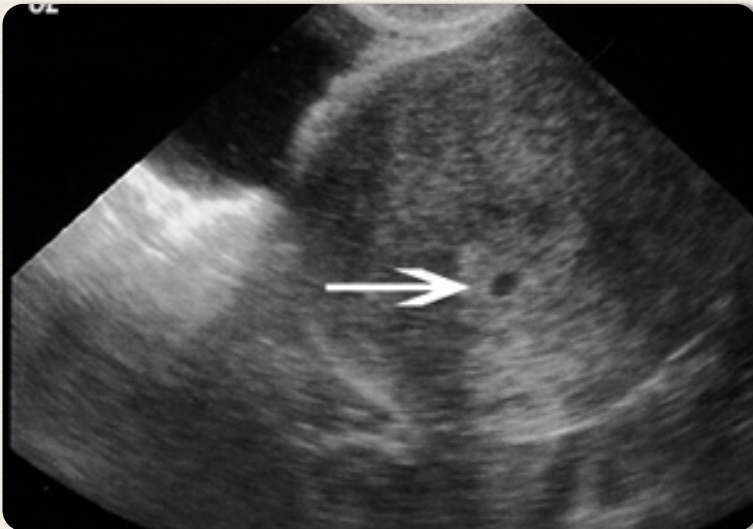


EMERGENCY MEDICINE CASES



SUMMARY OF EPISODE 23:
VAGINAL BLEEDING IN EARLY PREGNANCY
WITH DR. ROSS CLAYBO AND
DR. DAVID DUSHENSKI

Approach to vaginal bleeding in early pregnancy

Big Categories to Consider:

- Ectopic pregnancy
- Threatened/spontaneous abortion
- Anembryonic pregnancy
- Non obstetrical causes (vaginal laceration, neoplastic polyps, fibroids)
- Gestational trophoblastic disease

When taking a history, determine:

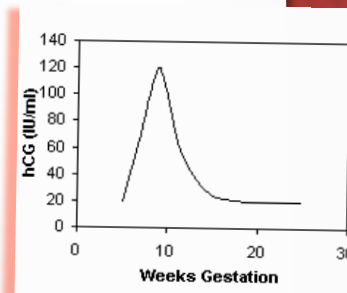
- ◇ degree and duration of bleeding,
- ◇ is the pain lateral or central,
- ◇ history of trauma,
- ◇ obstetric and fertility history, bleeding disorders, infections,
- ◇ previous miscarriage history.

Anembryonic Pregnancy:

Fertilized ovum that does not develop into a normal embryo. Presents with bleeding in 1st trimester & ultrasound showing a gestational sac without visualization of yolk sac or embryo at appropriate sizes. Management is similar to a missed abortion (see below) *once ectopic is ruled out.*

WHEN IS BHCG TESTING USEFUL?

BhCG levels become positive 8–11 days after conception. Levels peak at 10–12 weeks, then gradually decrease. ****Test all women of child-bearing age regardless of history suggesting possibility of pregnancy(1,2).**** Urine BhCG becomes positive 1 week later than serum tests, and may be *falsely negative* if urine is very dilute.



Is there value for serum progesterone?

Progesterone may identify patients who have high likelihood of viable intrauterine pregnancy (levels >22ng/mL), and patients who likely have a nonviable pregnancy (levels <5ng/mL)(3)—however, our experts believe it does not significantly change practice enough to warrant its use in the ED.

Key BhCG facts to remember:

- At expected time of missed menses: 2000IU/mL
- IUP visible by transvaginal ultrasound: >1500IU/mL
- IUP visible by abdominal ultrasound: >3000IU/mL
- Cardiac activity visible on ultrasound: >1500IU/mL by transvaginal >6500IU/mL by abdominal
- BhCG doubling time: 48–72 hours
- Levels becomes undetectable: 3–4 weeks postpartum

Work-up + Management of Abortion & Ectopic Pregnancy

Categories of Miscarriage/ Spontaneous Abortion

Threatened: bleeding with closed cervix and no evidence of fetal demise on ultrasound (U/S)

Risk of complete abortion is 50%, but if fetal heart rate seen (possible at >7 weeks), risk decreases to ~5%

Inevitable: open cervix, products of conception not yet expelled

Almost all progress to complete

Incomplete: products of conception not completely expelled, based on U/S or exam

Compete: All products expelled from uterus, bleeding usually minimal, and os closed

Missed: U/S shows fetal demise, but products remain in uterus, with or without bleeding or symptoms

Septic: rare result of pelvic instrumentation (esp. non sterile conditions), may be mistaken as PID

How should we manage stable patients with miscarriage?

Management options are expectant management, medical management (misoprostol 800mg inserted vaginally encourages passage of products), and surgical management (D&C).

Counseling in the ED must also address psychological concerns:

- use sensitivity and empathy,
- acknowledge distress and grief,
- reassure the patient that neither she nor her partner did anything to cause the miscarriage, and
- there is no increased risk for future miscarriages (if < 3 have occurred).

What is the value of the pelvic examination in stable patients?

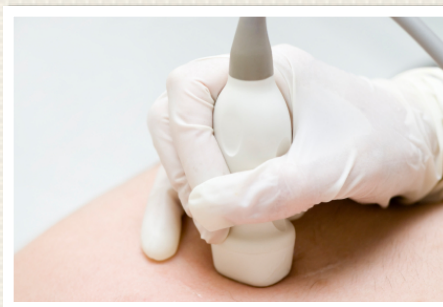If ultrasound findings are available and reassuring, our experts suggest a pelvic exam may be deferred. However, if high quality ultrasound is not available, or not definitive & reassuring, a pelvic exam is required to assess the uterus and adnexae. *The pelvic exam is also an opportunity for STI screening.*

What about unstable patients with miscarriage and bleeding?

Manage similar to all unstable bleeding patients (resus room, monitors, vascular access, IV fluid +/- unmatched O neg blood, foley). Investigate for DIC, and urgently consult OB/GYN.

Tranexamic acid (1g IV) +/- oxytocin (40U by IV in 1L NS at 150cc/hour) can be given to slow bleeding before definitive management (in the OR).

In an unstable patient with massive vaginal bleeding, a pelvic exam is indicated to identify a source and to look for and extract tissue found in the cervix.



Ectopic Pregnancy

Only 50% of patients have classic risk factors (past history of ectopic, tubal surgery, tubal ligation, infertility treatment, or PID). The classic triad of **abdominal pain** (80–90%), **missed menses** 4–12 wks after LMP (75–90%) & **vaginal bleeding** (50–80%) is NOT sensitive. Up to 25% lack the full triad, and 10% may have no symptoms. *Consider ectopic when a patient presents with syncope and has a positive BhCG.*

Vital signs may be falsely reassuring in ectopic pregnancy:

Patients with ectopics often have normal vital signs, *even with significant bleeding*, and may have a reflex bradycardia caused by a vagal response to intraperitoneal blood (4).

Physical examination findings in ectopic pregnancy (5):

- Abdominal tenderness (80-90%)
- Adnexal tenderness (75-90%)
- Adnexal mass (50%)
- Uterine enlargement (25%)
- Orthostasis (10%)

Pelvic exams can be completely normal.

Serial BhCG measurement is most useful to confirm fetal viability (BhCG should rise at least 66% over 48hrs) rather than to identify ectopic pregnancy. However if the BhCG >50,000, ectopic is very unlikely.

**VERY LOW BHCG (<1000)
DOES NOT RULE OUT
ECTOPIC; ULTRASOUND IS
STILL NEEDED!**

Bedside ED Ultrasound:

ED U/S for ectopic is very specific for ruling out ectopic (6), and involves looking for intrauterine pregnancy (IUP), and free fluid in the pelvis and abdomen. To confirm an IUP by U/S, a decidual reaction with a gestational sac and yolk sac (+/- fetal pole) must be seen **within** the uterus. Even if an IUP is seen, if the patient is unstable with free fluid in the abdomen, it may be a ruptured cyst or a “heterotopic”!

When to give Rhogam: Give Anti-D immunoglobulin to non sensitized Rh-D negative women to prevent development of RhD antibodies. It should be given as soon as possible after the immunizing event (within 72 hours) and effects last for 12 weeks.

How are ectopic pregnancies treated and what are the complications that may occur?

Treatment options for ectopic pregnancy

Expectant: in stable patients with a BhCG below 200 and not increasing, >75% will resolve spontaneously. Close monitoring is needed until BhCG <15.

Methotrexate (MTX): MTX is a folic acid antagonist that is up to 95% effective in appropriate patients (BhCG <5000, no fetal cardiac activity, ectopic mass <3–4cm, hemodynamically stable, no sign of rupture, reliable patient.)

Failure of MTX is related to BhCG level: Failure rates are approx. 15% with BhCG >5000 and 5% with BhCG <5000.

Prior to MTX treatment, blood tests must confirm normal liver and kidney function, and patients must be counseled to avoid folic acid and alcohol. Strenuous exercise and intercourse must also be avoided due to the risk of tubal rupture. Patients must also discontinue folic acid supplementation.

Surgical: for patients who do not qualify for or have failed other management, or patients who have intra-abdominal bleeding or are unstable, surgical management is indicated.

If a patient who received MTX returns with abdominal pain:

Abdominal pain is a common side effect of MTX treatment, but may indicate tube rupture (occurs in 4% of patients, usually 2 weeks after MTX treatment). Patients need a full workup for ectopic rupture: hematocrit, BhCG, and ultrasound to look for bleeding. If there are any signs of rupture, urgent OB consult is needed.

****Due to the risk of tubal rupture, do not do a pelvic exam on a patient who has had MTX treatment and presents with pain or vaginal bleeding. Begin workup for ectopic rupture and consult OB/GYN.****

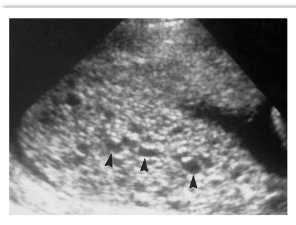
Molar Pregnancy

What is a molar pregnancy:

Molar pregnancies are tumors from abnormal fertilization of an ovum, with overproliferation of trophoblastic tissue. A complete mole has no fetal tissue, while an incomplete mole has abnormal fetal tissue.

Most common presentation is vaginal bleeding, but they can present with ovarian torsion due to generation of reactive cysts.

The uterus will be larger than dates, and ultrasound may show a “snowstorm” appearance. Ultrasound is not sensitive for molar pregnancy in first trimester.



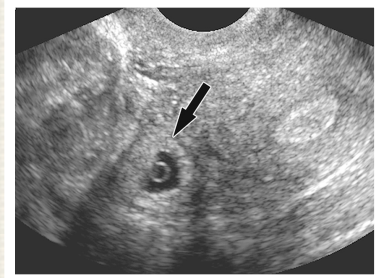
Patients may present with preeclampsia and/or hyperthyroid symptoms due to very high BhCG levels (>100,000).

Treatment is surgery, and includes a workup for metastatic disease. 15–20% of complete molar pregnancies and 2% of incomplete become neoplastic, so patients need a CXR and liver enzyme measurements, and close follow-up with OB/GYN.

References:

- 1) Minnerop et al. Am J Emerg Med. 2011; 29:212
- 2) Ramoska et al. Ann Emerg Med. 1989;18:48
- 3) Buckley et al. Ann Emerg Med. 2000;36:95
- 4) Hick et al. Am J Emerg Med. 2001;19:488
- 5) Dart et al. Ann Emerg Med. 1999;33(3):283
- 6) Stein et al. Ann Emerg Med. 2010;56(6):674


ECTOPIC PITFALLS



AVOID these major pitfalls of diagnosing ectopic pregnancy in the emergency department:

- assuming low BhCG rules out ectopic
- relying on the “classic triad”
- relying on inexperienced ultrasonographer or non-hospital ultrasound lab reports
- assuming no products of conception seen on U/S means it was a complete abortion (and not an ectopic)
- failure to appreciate degree of blood loss
- failure to consider heterotopic* if unstable and IUP seen on U/S
- failure to assure adequate follow up if no IUP is seen or if the ultrasound is indeterminate

**heterotopic risk of 1 in 30,000 pregnancies rises to 1 in 100 if the patient is receiving fertility treatments*



SUBSCRIBE TO EMCASES