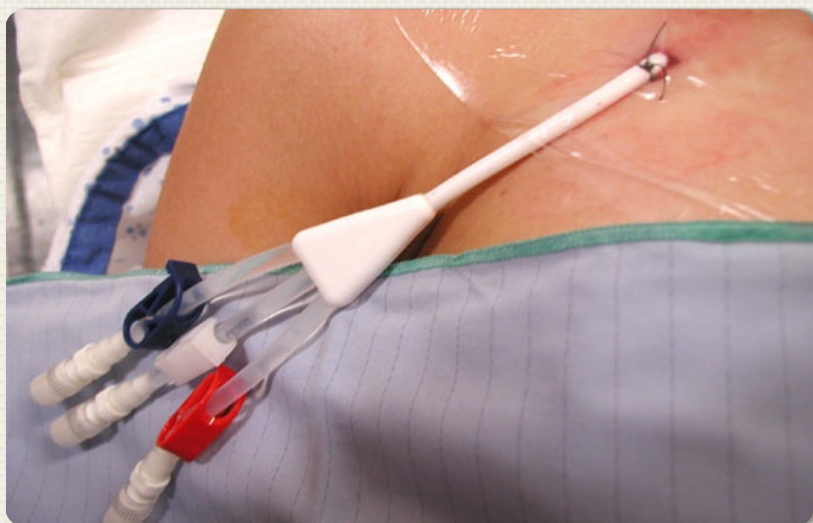

# EMERGENCY MEDICINE CASES



EPISODE 30 WITH DR. JAMIE  
BLICKER & JORDAN CHENKIN

## Pearls, pitfalls, tips and tricks for procedures: Part 1

### CENTRAL LINES

**Are they the best option for fluid resuscitation?** A wide bore short peripheral line has a faster flow rate than a central line. Triple-lumen catheters should not be chosen if rapid volume resuscitation is required; consider placing a sheath introducer.

**Location Considerations:** Choose the location you are most comfortable with, then consider the patient's clinical scenario:

–for **hypovolemic** pts, think subclavian (doesn't collapse as quickly),

– **coagulopathic** - choose compressible site (femoral or IJ),  
–avoid sites with **distorted anatomy** or trauma proximal to the site (i.e. femoral is not a good choice for a patient bleeding in the abdomen),  
–For patients at high risk for pneumothorax, consider femoral  
–**transvenous pacemaker insertion** is easiest through right IJ, or left subclavian.

**What about catheter related bloodstream infections?** Risks are highest for lines inserted in very ill, crashing patients (1). Reduce the risk by

using strict sterile technique! With strict technique, rates of infection may **not** be higher in the femoral site as previously thought (2,3). DVT risk is likely **not** higher in the femoral site (4). Antibiotic-impregnated and heparin coated catheters also lower line infection rates.

**The central line bundle** (5) reduces line infections, and should be used whenever possible, including a checklist and observer. Finally, use **ultrasound guidance**, as it has been proven to improve the chances of getting the line in on the first attempt which reduces complication rates.

### WHAT ABOUT ARTERIAL PUNCTURE?

Internal Jugular lines are associated with higher risk of arterial puncture compared to subclavian. U/S guidance reduces the risk, and for patients with IJ lying over the carotid artery, a lateral (posterior to the SCM) approach may be used. Confirm the catheter is in the vein directly with ultrasound, indirectly by a pressure transducer, by **sending a VBG**, or by **shooting a CXR** with the guidewire clamped at the skin. (If you do end up inserting a catheter into an artery, *don't remove it!* Call vascular surgery right away!)

### What about coagulopathic patients?

Choose a compressible site (femoral or IJ) and have the most experienced clinician with bedside ultrasound guidance to improve success on first puncture. The literature suggests there is no indication to correct a high INR or low platelets prior to placing a central line (6). A scalpel nick is not necessary for a triple lumen catheter; the IJ is superficial and at risk of injury by the scalpel. Finally, consider using a peripheral catheter in the external jugular or IJ rather than a central line for these patients.

# Central lines (cont'd), and intraosseous catheters:

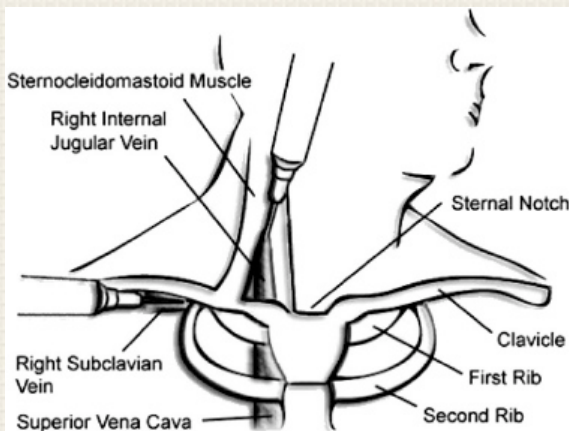
## Landmarking for Central Lines:

Blind landmarking may be necessary, if Ultrasound guidance is not available.

**Femoral:** If the artery cannot be felt, place a thumb on the pubic symphysis and index finger on ASIS, and use the apex of the V-shape of your 1st web space to **find the femoral artery, then move 1cm medial at level of inguinal ligament.** The optimal position is usually with the hip in external rotation & abducted (7).

## For Supraclavicular

**Subclavian:** Use the “pocket shot” by inserting the needle 1cm lateral from the clavicular head of the SCM, and 1cm posterior to the clavicle. Aim toward contralateral nipple with needle 15° above horizontal.



## For Infraclavicular Subclavian:

Aim below the clavicle, 1/3 from the medial head. Place a finger in the sternal notch and thumb at 1/3 along the clavicle, and insert the needle just lateral to the thumb at the pectoral triangle. Aim to have the needle just under the clavicle, under your thumb. Keep angle shallow.

**For Internal Jugular:** Use Trendelenberg, with slight head rotation. Palpate the carotid pulse, and insert the needle lateral to carotid at the apex of the triangle formed by the 2 heads of the SCM. Angle toward ipsilateral nipple, and when inserting the guidewire, use a low angle and watch the monitor during guidewire insertion.

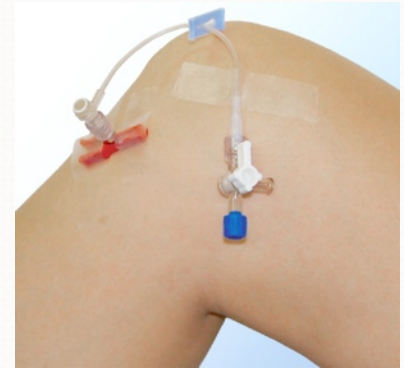## Pearls & Pifalls:

- 1) Don't insert the needle and sweep blindly for the vein; remove and reinsert if necessary.
- 2) Double-check the guidewire is in the vein by U/S *before dilating*.
- 3) Prep both IJ and SC on same side, in case another location needs to be attempted. (Don't switch sides, and risk bilateral complications.)
- 4) Try withdrawing the guidewire and rotating slightly if you have trouble advancing it.

## How to prevent an air embolism:

- 1) Use Trendelenberg
- 2) Occlude catheter hubs at all times and aspirate all air
- 3) Insert on exhalation.

**Remember: With procedures, practice and repetition helps make the procedure automatic, which reduces the rate of complications and allows you to think about other aspects of patient care!**



## INTRAOSSUEOUS ACCESS:

Consider an IO for any patients where IV access is anticipated to be difficult. **Any medications and fluids that can go through the IV/CVC can be administered through the IO.\*** An IO is quicker and easier to place than an IV, and less training and experience is required. Pitfalls with insertion are usually due to errors in landmarking.

## How accurate is the blood?

Blood samples are accurate for Hb, Na, Cl, Gl, Cr and for crossmatch, but not for CO<sub>2</sub> or potassium.

**Where does the IO go?** In kids, use the proximal tibia, and in adults the distal femur or proximal humerus may be preferable. **Confirm placement by aspirating blood** and flush the catheter with 20mL of saline. Check that local compartment pressures are not increasing (which indicates leak into interstitium).

**Places to avoid:** Avoid broken bones, sites of previous IO attempt (fluid will leak), or sites near infections or previous surgeries. Discard the first few cc's before sending bloodwork.

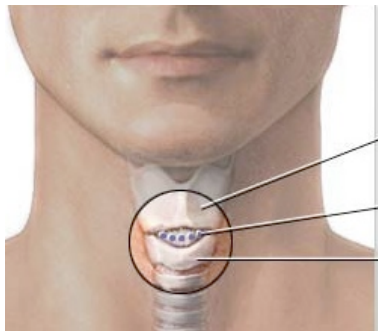
\*Avoid calcium after ceftriaxone.

# Finally: all about surgical airways!

## SURGICAL AIRWAYS

**Approx. 1% of intubations in the ED are surgical airways; most are in the setting of trauma.** The procedure for traditional surgical cricothyrotomy uses the following basic techniques.

- 1) **Landmark:** Palpate the cricothyroid membrane between the thyroid cartilage and the cricoid cartilage (approx 4 fingers above the sternal notch).



- 2) **Stabilize** the larynx with your nondominant hand *throughout the procedure*. **Insert an 18g needle through the skin** and pull back until air enters the syringe. Leave needle in to landmark.
- 3) Make a **vertical skin incision** 2cm long from bottom of cricoid to the thyroid cartilage and membrane.
- 4) **Cut horizontally** 1cm across the lower part of the membrane, and insert the tracheal hook (with upward traction).
- 5) **Expand the hole** with the dilator, and insert a #4 cuffed trach tube or a #6 cuffed ET tube along the dilator, then rotate 90 degrees. Don't push the tube in more than ~5cm to avoid intubating R lung.
- 6) Confirm placement by usual methods + easy, smooth passing of NG tube through the tracheal tube.

**Alternative methods:** A bougie assisted technique (see YouTube - [www.youtube.com/watch?v=wVQFJR7qmrQ](http://www.youtube.com/watch?v=wVQFJR7qmrQ)), with the tube passed over a bougie (8) may be better for novice operators (9). A Seldinger guidewire technique may also be used. The "4-step technique" involving only 1 incision (horizontal) may be faster but has more bleeding complications.

**Transtracheal jet ventilation:** A large bore needle (12G or 14G) through the cricothyroid membrane, attached to a syringe and adapter, can oxygenate a patient for a brief period of time. This is a *temporizing method*, less reliable than surgical cric (10), and can only oxygenate, not ventilate.

## PERICARDIO-CENTESIS

Consider pericardial effusion with tamponade in any patient with unexplained SOB. *Tamponade is a clinical diagnosis with ultrasound helping to confirm!* Our experts recommend an apical approach, with U/S (11). For apical pericardiocentesis, find a pocket of fluid on U/S closest to the probe with the patient in L lateral decubitus position. Use U/S to determine the distance from the skin to the fluid. *For full details, please refer to the podcast audio*, but our experts suggest the following tips:

- 1) Once blood is aspirated, inject agitated saline under U/S guidance to confirm the needle is in the pericardium.
- 2) Avoid positive pressure ventilation if possible in the patient who is crashing from tamponade, as it may worsen the tamponade.

## References:

- 1) Reid C et al. Ann Emerg Med 2010;56:492.
- 2) Deshpande KS et al. Crit Care Med 2005;33:13.
- 3) Whalen F. Ann Intern Med 2012;157:JC5.
- 4) Cochrane Database Syst Rev. 2012 Mar 14;3:CD004084
- 5) Berenholtz et al. NEJM 2004;32:2014.
- 6) Baombe JP et al. Emerg Med J 2011;26:536.
- 7) Werner SL et al. J Emerg Med 2008;35:73.
- 8) Curtis K et al. Acad Emerg Med 2012 Jul; 19:876.
- 9) Hill C et al. Acad Emerg Med. 2010;17:666
- 10) Hubble MW et al. Prehosp Emerg Care. 2010;14:515.
- 11) Tsang TS et al. Mayo Clin Proc. 2002;77:429.

Stay tuned for Episode 31, when we review tips and techniques for tricky lumbar punctures, pneumothorax management, fracture reduction under ultrasound, and *many more!*



SUBSCRIBE TO EMCASES



Division of Emergency Medicine  
UNIVERSITY OF TORONTO