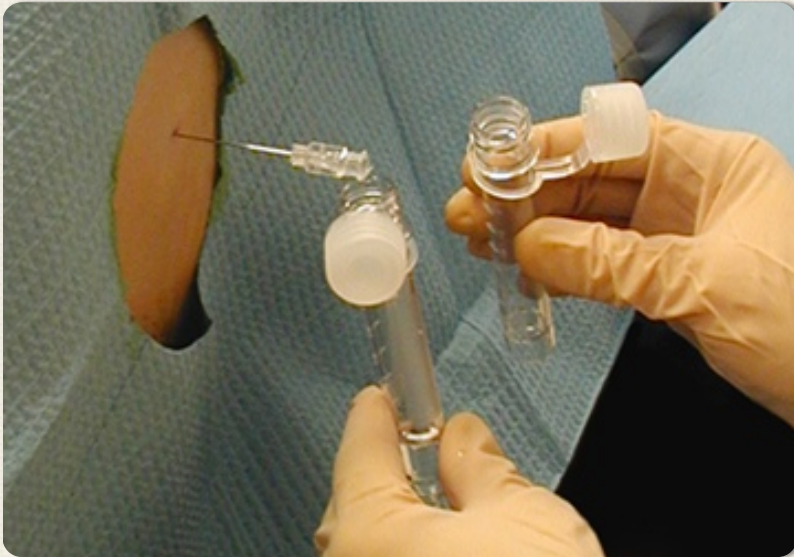


EMERGENCY MEDICINE CASES



EPISODE 31: PROCEDURES PEARLS AND PITFALLS/TIPS AND TRICKS - PART 2

WITH DR. JAMIE BLICKER AND DR. JORDAN CHENKIN

Tips for a successful lumbar puncture:

Which patients need a CT first?

Herniation after LP is extremely rare. Mass effect on CT does not predict herniation, and normal CT does not eliminate the risk. Obtaining a CT prior to the LP can **delay diagnosis** and risk negative culture from the LP tap.

Always give antibiotics before CT especially if delay is anticipated. Our experts recommend selective use of CT. Clinical findings can be used to identify patients who need a CT scan (I) and guidelines from the Infectious

Diseases Society of America identified **six indications for CT head before LP** (2):

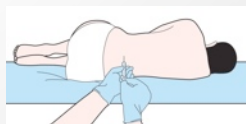- history of immune compromise
- known focal CNS disease
- seizure in the past week
- papilledema
- altered LOC
- focal deficit on exam.

Ultrasound can be used to assess **optic nerve diameter** for

papilledema. The basic technique involves applying a **high frequency linear probe on the patient's closed eyelid** with a neutral gaze. Find the optic nerve in the retina surface, and **measure optic nerve sheath diameter at a point 3 mm posterior to the retina.** **>5 mm diameter** is abnormal, as is a convex bulge in the optic nerve, which suggests papilledema.

WHAT'S THE BEST POSITION?

There is no evidence that one position is best for the LP, but opening pressures are only accurate in lateral decubitus. This position may also help the patient stay still, and prevents a fall if syncope occurs. Remember to fully align the spine, with hips perpendicular to the bed, and a pillow under the head. If choosing a sitting position, which may optimize interspace diameter, place feet on a stool to flex hips, and don't over flex the neck.



Tips for a "champagne tap"

Our experts recommend using lidocaine **with** epinephrine to create a wide anesthesia field, and inserting the needle through sterile 2x2" gauze. Clean the head of the needle if blood appears at the initial part of the tap to avoid contaminating the entire sample with RBCs from the initial clot. Only reposition/re-angle the needle when it is withdrawn to the skin surface, and consider moving to another interspace rather than reattempting at the same site to reduce the risk of a traumatic tap.



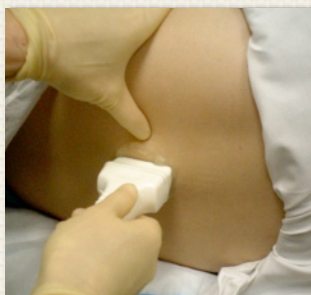More LP tips:

Post-LP Headache: There is no

evidence for bed rest after LP to reduce post-LP headache. Our experts recommend reducing the risk by using a **smaller gauge** needle (22G or smaller if available), and an atraumatic/non-cutting needle if possible(3). Reinsert the stylet prior to needle removal, and keep the needle bevel parallel to the spine.

Ultrasound for Landmarking:

Ultrasound can be used if landmarks are not palpable, to improve accuracy without adding to procedure time (4). Position the patient for the LP and **use curved array probe in the transverse and mark the midline**. Then estimate the distance required to reach the ligamentum flavum, and the angle required for the needle, and **turn the probe to longitudinal to find and mark the interspace**.



For certain patients who cannot flex their back, a **lateral (aka para-median approach)** may help. Insert the needle 1 cm lateral to the midline, and direct it slightly cephalad and medially to reach the midline.

Coagulopathic patients:

Our experts suggest correcting INR > 1.4 and platelets < 50k before an LP. Consult hematology where possible and consider LP indications and methods of coagulopathy correction *carefully* in each patient.

Management of pneumothorax

Spontaneous Pneumothorax:

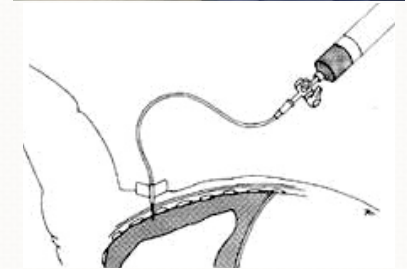
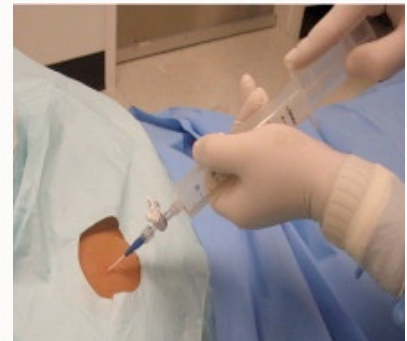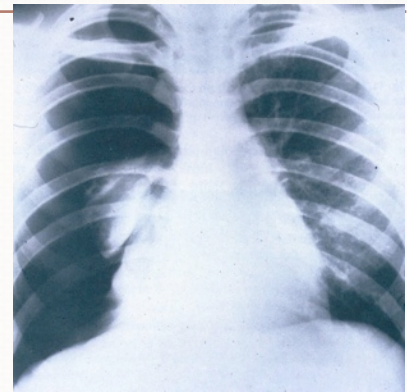
Asymptomatic patients without lung pathology who have a small (<3 cm from the apex, or <20% lung volume) primary, spontaneous pneumothorax may require **only observation and a repeat CXR**. Spontaneous pneumothoraces that are **larger or symptomatic**, or **secondary to lung pathology** should be treated.

For primary pneumothorax, evidence suggests needle aspiration is non-inferior to chest tube drainage (5).

A 14 or 16G angiocath connected to a 3 way stopcock can be used for serial aspirations with a large syringe. Pigtail catheters/small bore pleural catheters with a Heimlich valve may be used instead. They produce less pain than a chest tube, and allow for outpatient management, however they tend to kink, clog, and displace so require careful insertion and followup. An outpatient protocol using small bore pigtail catheters demonstrated >80% success rate for resolution and patient discharge home (6).

Tips for Pleural Catheter Insertion:

- do not tunnel the catheter on insertion (or it will kink) - insert the catheter straight in, over the rib to avoid the neuro-vasc bundle
- angle the tube **toward the apex** and insert to the hub, then attach the Heimlich valve
- warn the patient pleural fluid may drain, and they may loosely attach an open bag to catch the fluid



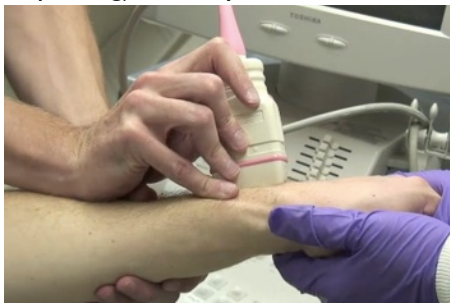Pleural catheters are usually not **suitable for secondary pneumothoraces**, as these have a high rate of reoccurrence and risk of tension pneumothorax. Also, they should not be used if blood, pus, or large amounts of pleural fluid are present. **These patients all need a large-bore chest tube, and admission to hospital**. Our experts recommend if patients are discharged with pleural catheters, using a standard flow-sheet with assessments every 24 hours and a stepwise advancement of methods if it does not initially resolve. (I.e. low GOMCO suction if underwater seal alone does not work.)

REDUCE A FRACTURE WITH ULTRASOUND

Cortical and cortex disruption shows up well on ultrasound, thus ultrasound can be used to **visualize occult fractures** (sternum, scaphoid, rib), to guide needle positioning **for a hematoma block**, and to verify success of **fracture reduction**. Using ultrasound may improve success of fracture reduction (7).

Procedure for U/S imaging for fracture reduction:

- 1) position the limb for reduction
- 2) use copious gel to float the probe above the skin, along the longitudinal axis, and center over the cortex
- 3) side proximal/distal to visualize the fracture and assess angulation
- 4) save the image on the machine
- 5) perform the reduction and recheck the fracture appearance (before splinting) to verify success.



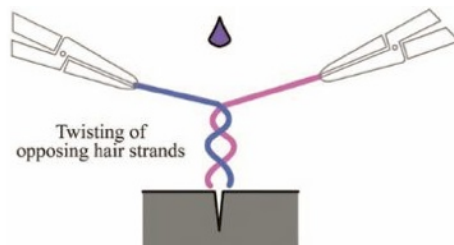
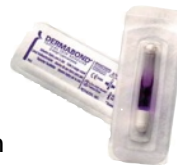GLUE FOR DENTAL FRACTURES:

ED treatment for dental fractures with exposed dentin or pulp (Ellis 2–3) typically requires using cement to cover the dentin until the patient can seek definitive management (8). **Skin glue may be used as a temporary barrier** rather than of dental cement. Skin glue application will cover the

exposed pulp or dentin and **relieve most of the pain**, and is quicker to apply than dental cement, and easier to access and prepare.

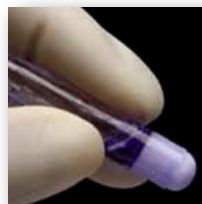SKIN GLUE FOR SCALP LACERATIONS

Although the “hair apposition technique” can be used for closing scalp lacerations, it may be too hard to grasp and twist shorter hair. Our experts recommend a **modified** “hair apposition technique,” which works for shorter hair (>1 cm) (9). First, grasp hair with a hemostat or a needle driver, then twist the strands together to pull the wound closed. Carefully apply glue only to the twist, and avoid excess glue dripping into the wound. See figure below (10).



NAILBED INJURIES

Apply skin glue to the dry surfaces at the edge of a lacerated nail or nail bed to **re-implant a nail**, rather than using sutures. Use a finger tourniquet as needed to provide a dry surface for glue adhesion. One study suggests skin glue is faster and not inferior to suture for **repair of nailbed injuries** (11).



REFERENCES:

- 1) Hasbun R et al. NEJM 2001; 345:1727.
- 2) Tunkel AR et al. Clin Infect Dis. 2004;39:1267.
- 3) Alcock A, Salter R. Emerg Med J. 2013; 30:80.
- 4) Nomera JT et al. J Ultrasound Med. 2007;26:1341.
- 5) Zehtabchi S, Rios CL. Ann Emerg Med. 2008;51:91.
- 6) Hassani B et al. Acad Emerg Med. 2009;16:513.
- 7) Ang SH et al. Am J Emerg Med. 2010; 28:1002.
- 8) Hile LM and Linklater DR. Ann Emerg Med. 2006;47:424.
- 9) Karaduman S et al. Am J Emerg Med. 2009;27:1050.
- 10) Lin, Michelle. ACEP News, April 2010.
- 11) Strauss EJ et al. J Hand Surg Am. 2008;33:250.



SUBSCRIBE TO EMCASES



Division of Emergency Medicine
UNIVERSITY OF TORONTO